

MORPHOLOGICAL AND MORPHOMETRICAL CHANGES THAT OCCUR IN ENDOMETRIUM OF AWASI EWES DURING DIFFERENT STAGES OF PREGNANCY

A. M. Elias

Department of Anatomy, College of Veterinary Medicine, University of Mosul , Mosul , Iraq.

(Received 14 May 2014 ,Accepted 23June 2014)

Keywords; Awasi sheep, epithelium, pregnancy.

ABSTRACT

Sixteen utri of Awasi sheep at different stages of pregnancy were used in this study .The intercaruncular surface epithelium was pseudostratified at the early stage of pregnancy and then changed gradually to simple columnar after day 50 Of pregnancy. At day 118 it become low columnar or simple cuboidal and decreased in height .

The glandular epithelium was mainly simple columnar and showed high secretory activity during the studied of pregnancy stages. The glandular diameter and their lumen was increased with the advancement of pregnancy . The gland showed saculation at late stages of pregnancy .

INTRODUCTION

During pregnancy , the ruminant endometrium secretes an albuminous fluid known as the uterine milk into the space between the uterine epithelium and the chorion (1). Many authors studied the ruminant endometrium during different stages of pregnancy (2;3;4) . however, no study has been done concerning the endometrial changes that occur in the endometrium of local Awasi sheep during pregnancy. The aim of the present work , to explore the morphological and morphometrical changes that may occur in the endometrium of pregnant Awasi sheep.

MATERIALS AND METHODS

Sixteen pregnant sheep uteri were obtained from the slaughter – house and the pregnancy stages were considered according to the crown – rump length . Tissue specimens were processed fore routine light microscopic study (5) . The uterine glands were classified into two groups according to their location . Superficial glands refer to those located in the upper part of the stroma towards the uterine lumen . Basal glands

refer to those located in the lower part of the stroma near the muscular layer . In each section , at least five glands showing a round outline were measured . height of intercaruncular uterine surface epithelium, diameter , lumen and the height of glandular epithelium was calculated using ocular micrometer in the different stages of pregnancy.

RESULTS

1- Intercaruncular surface epithelium :-

At day 50 of pregnancy the surface epithelium was sloughed in many sites due to preparation , but the intact patches (Fig. 1) appeared as pseudostratified columnar , occasionally simple columnar being observed . The highest epithelium of 18.6 μm (Table 1) was recorded after this stage . Some degree of vacuolation was present in most samples . the nuclei appeared round or ovoid in shape(fig 2) .

At day 60 the majority of the epithelium was sloughed with the fetal membranes , but what did remain indicated that it was low simple columnar 13.3 μm (Table 1 , Fig 3) and was vacuolated . the nuclei appeared also ovoid in shape . At days 80 , 90 and 100 the surface epithelium was mainly similar to day 60 of pregnancy (Table 1) . At day 118 the epithelium decreased in height and became 11. 9 μm (Table 1) and the intact sites appeared low simple columnar to cuboidal (Fig. 4and 5) .

2- uterine glands :-

At day 50 the glandular epithelium was simple columnar with round or oval nuclei which were basally located (Fig.6) . Both glands appeared coiled , hypertrophied and showed high secretory activity with vacuolated epithelium . The diameter of superficial glands was 70.4 μm (Table 1) and larger than that of the basal ones 45.1 μm , the epithelium of the superficial glands was 10.6 μm and higher than that of the basal glands 8 μm .

At days 60 , 80 and 90 the glands had mostly similar features to those of day 50 (Table 1) . At days 100 and 118 the epithelium showed high secretory activity and was simple columnar with round or ovoid nuclei and it was vacuolated . The superficial and basal glands increased in diameter 82.2 μm and 84.8 μm , 58.3 μm and 58.8 μm respectively (Table 1) .

Their lumina also increased in diameter 62.8 μm and 66.3 μm , 42.4 μm and 42.9 μ respectively (Table 1) . The epithelial height especially of the superficial glands

decreased and was 9.5 μm respectively (Table 1) . About 50% of glands were irregular in shape and the others had dilated lumen and tend to be sacculated .

Table (1) : Tabular view of the pregnant uteri . Mean of the results of a measurement on the surface epithelium and uterine gland / μm

Day of pregnancy	Height of the surface epithelium	Diameter of the uterine glands		Diameter of the gland lumen		Height of the gland epithelium		Magnification
		superficial	basal	superficial	basal	superficial	basal	
50	18.6	70.4	45.1	49.6	29.2	10.6	8	40X
60	13.3	74.2	34.5	48.5	19.3	12.7	8	40X
80	13.3	75.5	53	51.7	31.8	11.9	10.6	40X
90	13.3	73.1	45.1	53.5	30.5	9.8	7.4	40X
100	13.3	82.2	58.3	62.8	42.4	9.5	8	40X
118	11.9	84.8	58.8	66.3	42.9	9.3	8	40X

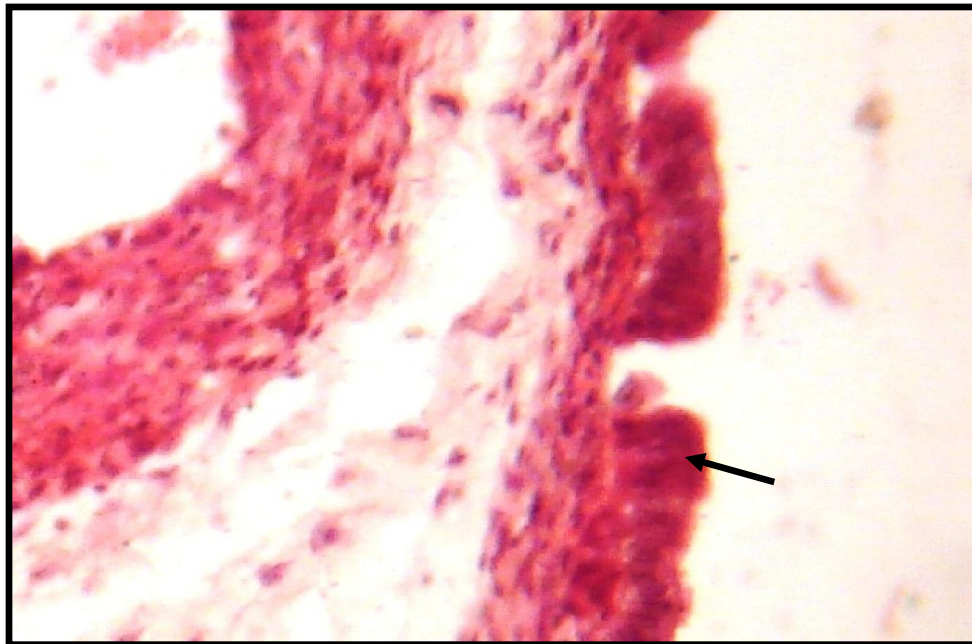


Fig.(1) Photomicrograph of intercaruncular area showing the pseudostratified columnar surface epithelium (arrow) at day 50 of pregnancy . H&E stain . (450 X).

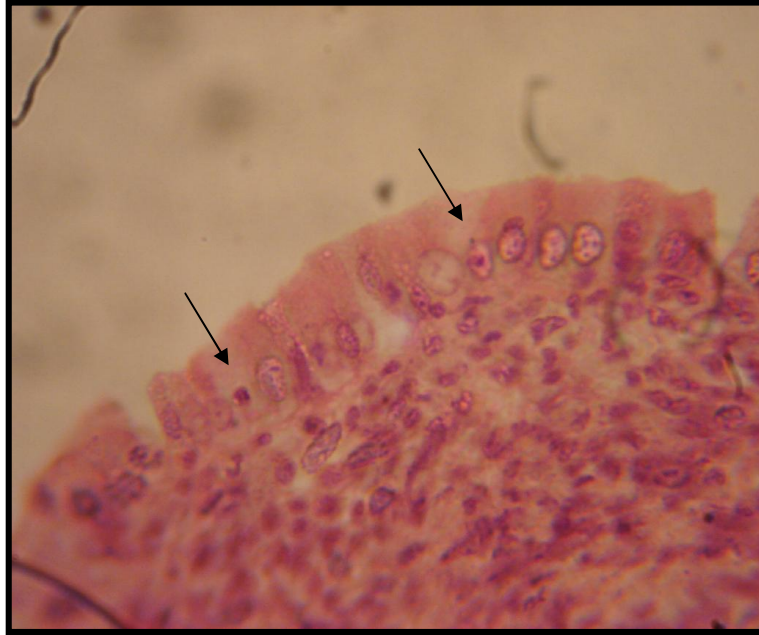

FIG.2: Photomicrograph showing some degree of vacuolation in the endometrial surface epithelium (arrow) at day 50 of pregnancy . H&E . 560X .

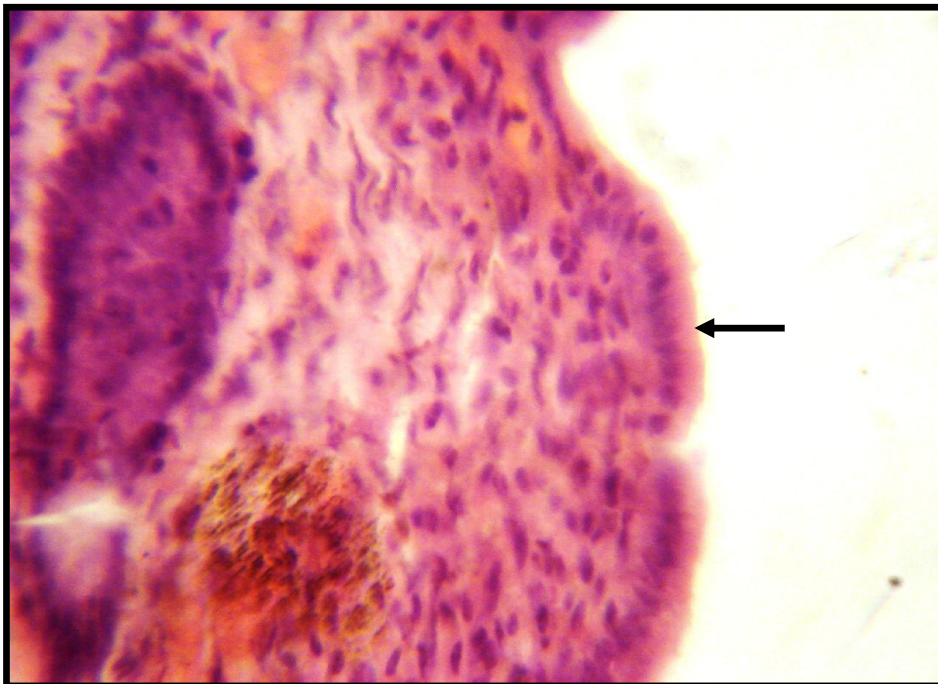


Fig.(3) Photomicrograph showing the low simple columnar surface epithelium(arrow) at day 60 of pregnancy . H&E stain . (450 X).

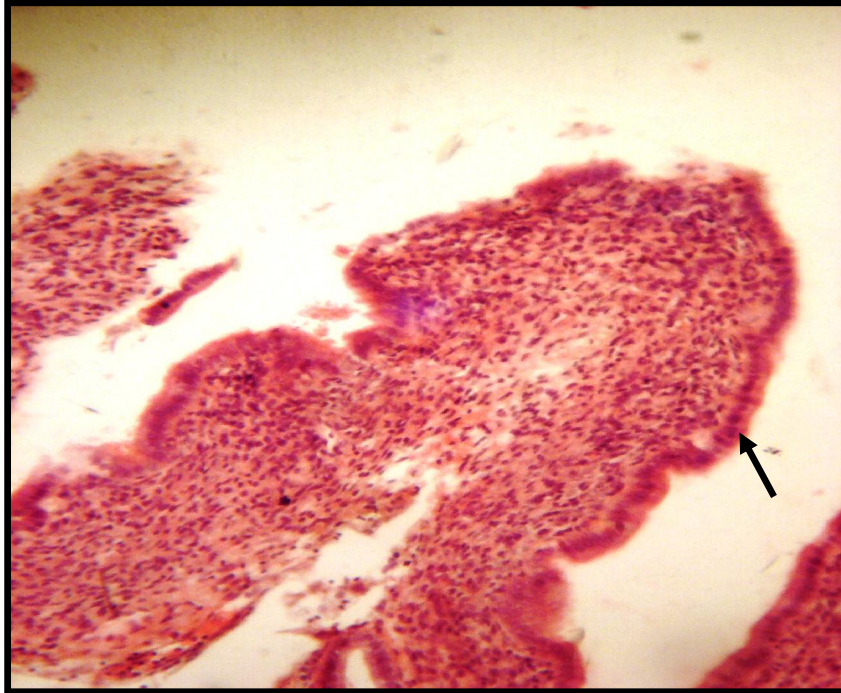


Fig.(4) photomicrograph showing the low simple columnar to cuboidal surface epithelium(arrow) at day 118 of pregnancy . H&E stain . (145 X).

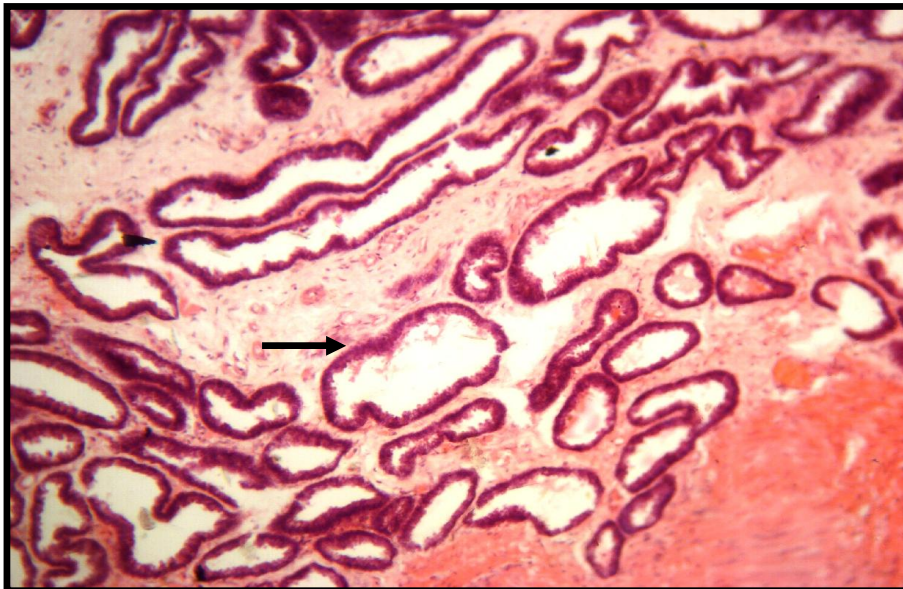


Fig.(5) Photomicrograph showing the irregular shaped basal glands at day 118 together with sacculated one (arrow) . H&E stain . (90 X).

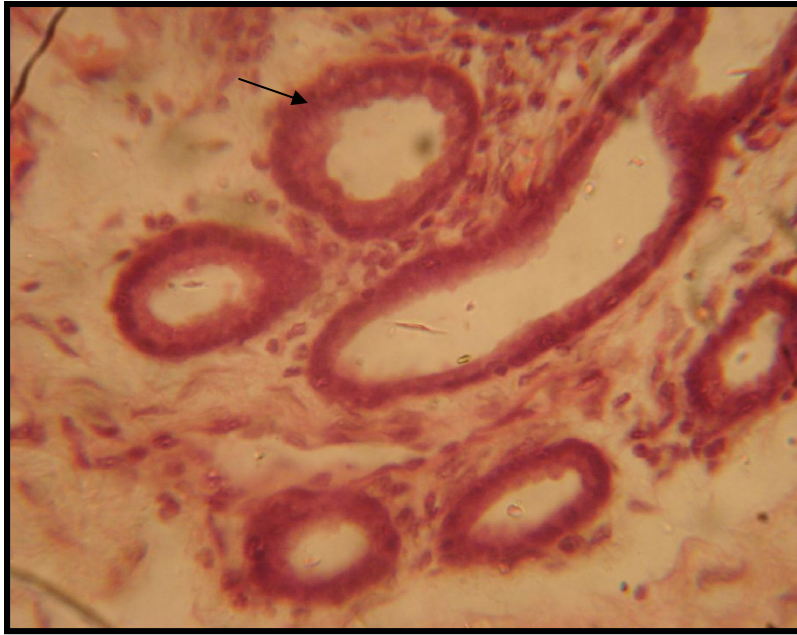


FIG.6: Photomicrograph showing simple columnar glandular epithelium (arrow) at day 50 of pregnancy . H&E . 450 X .

DISCUSSION

1- Intercaruncular surface epithelium :-

The surface epithelium is pseudostratified columnar and / or simple columnar in ruminants during the estrous cycle (6, 7, 8, 9,10, 11,12,13) . Similarly the present work revealed that the surface epithelium is mainly pseudostratified columnar and of height $18.6 \mu\text{m}$ at day 50 of pregnancy and at days 60 , 80 , 90 , and 100 of pregnancy the epithelium appeared lower and changed into simple columnar ($13.3 \mu\text{m}$) and becoming ($11.9 \mu\text{m}$) at day 118 . In bovine uterus the surface epithelium was generally low at estrus but high in luteal phase (14, 15 , 9) . In addition , a reduction in height of the bovine uterine epithelium on day 18 was the first detectable maternal response to the presence of the blastocyst within the lumen (8 , 9) , but the epithelium above the caruncles was entirely destroyed on day 7 in post parturient ewes (16 , 17) and in goat postpartum (16) . In support of the observations of (8) and (9) during early pregnancy in bovine endometrium , results in the current study indicated that the intercaruncular epithelium is intact except that detaching or sloughing with the fetal membranes . However , (19) confirmed that the intercotyledonary endometrium of sheep remains thin at about med – pregnancy .

2- Uterine glands :-

Simple coiled and branched tubular glands lined with simple columnar epithelium are directly associated with the secretion of progesterone , being active during diestrus (14 , 19 , 7, 10 , 11) , pregnancy in cow (21 , 9) and in roe deer (20) . In agreement with (21 , 9) , the glands were classified into superficial and basal glands according to their location . The superficial glands were larger and their epithelium was higher than basal ones . Both glands increase in diameter and lumen with the advancement of pregnancy specially at days 100 and 118 . This concurs with view of (21 , 9) in bovine uterus during early pregnancy . Contrary to the suggestion of (21) it was noticed that the epithelium of the superficial glands decrease in height and the basal glands epithelium remain on almost constant height . however , the glandular epithelium decrease in height in roe deer at the time of implantation (20) , in bovine during early pregnancy (9) and considerably degenerated at day 7 in post parturient ewes (17) . In support of the investigation of (21 , 9) the glands showed irregular shape and the others had dilated or cyst – like appear gradually in late stage of pregnancy .

التغيرات الشكلية والقياسية التي تحدث في بطانة رحم الأغنام العواسية في مراحل الحمل المختلفة

عبد السلام متي الياس

فرع التشريح ، كلية الطب لبيطري ، جامعة الموصل، الموصل ، العراق .

الخلاصة

استخدمت ١٦ عينة من ارحام الاغنام العواسي في مراحل مختلفة من الحمل لغرض الدراسة . كانت الظهارة بين اللحيمات مطبقة كاذبة في الفترة المبكرة من الحمل ثم تغيرت تدريجيا إلى عمودية بسيطة بعد اليوم الخمسين من بداية الحمل وأصبحت عمودية بسيطة أو مكعبة بسيطة في اليوم ١١٨ من الحمل. كانت الظهارة الغدية عمودية بسيطة وتبين أن نشاطها الإفرازي عالي خلال مراحل الحمل المدروسة . ازداد قطر وتجويف الغدد مع تقدم الحمل كما أظهرت الغدد تقيسا" في الفترة المتأخرة من الحمل.

REFERENCES

- 1- Hoys, A.D. (1972) . The endometrial glands of the pregnant sheep : an ultrastructural study . J. Anat. 111 : 55 – 67 .
- 2- Ahmadi , M.R. ; Nazifi , S.A. (2006) . Evaluation of reproductive status with cervical and uterine cytology in fat tailed sheep . Comp. Clin. Pathol. 15 : 161 – 164 .

- 3- Scott , J.L. ; Ketheeson , N. ; Summers , P.M. (2006). Leucocyte population changes in the reproductive tract of the ewe in response to the insemination . *Reprod. Fertile. Dev.* 18(6) : 627 – 34 .
- 4- Hansen , P.J. (2007) . Regulation of immune cells in the uterus during pregnancy in ruminants . *J. Anim. Sci.:* 85 (13 suppl) : E30 – 1 Links .
- 5- Kiernan J A. (2010). *Histological and histochemical methods, theory and practice*, 4th ed. Scion Publishing Ltd., London,UK,pp . 281,282.
- 6- Sundaravadanan , V.K. ; Venkataswamy , V. (1973) . Histology and histochemistry of bovine uterus . *Abstr. 5972. Indian J. Anim. Sci.* 43:1050 – 1053 .
- 7- Jo Ann Eurell, , Brian L. Frappier, .(2006). *Dellmann's Textbook of Veterinary Histology*, Wiley-Blackwell, USA
- 8- King , G.J. ; Atkinson , B.A. ; Robertson , H.A. (1981) . Development of the intercaruncular areas during early gestation and establishment of the bovine placenta . *J. Reprod. Fert.* 61: 469 – 474 .
- 9- Alias , A.M. (1982) . Histological and histochemical studies of the bovine uterus during early pregnancy . PhD thesis
- 10- Banks, W.J. (1986) . *Applied veterinary histology*. 2nd ed. Williams & wilkins ,Baltimore
- 11- Samuelson , D.A. (2007) . *Textbook of veterinary histology* . Saunders.
- 12 .Bacha, W.J. and Bacha ,L.M. (2000). *Color atlas of veterinary histology*. Springer -Verlag. New York.
- 13 - Banks, WJ. (1993) . *Applied veterinary histology*. 3rd ed. Williams & wilkins ,Baltimore , pp : 221.
- 14- Johnson , K.J.R. (1965) . Cyclic histological changes occurring in the endometrium of bovine . *Res. Bull. Idaho agric. Exp. Stn. No. 63* : pp22 .
- 15- Yoshio , K. ; ULF, S. (1970) . Cyclical changes in the fine structure of bovine endometrial gland cell . *Zellforsch* . 104 : 60 – 86 .
- 16- Vanwyk , L.C. ; Vanniekerk , C.H. ; Belonje , P.C. (1972) . Involution of the post partum uterus of the ewe .*J.S. Afri. Vet. Assoc.* 43 : 19 – 26 .
- 17- Krajnicakova , M. ; Bekeova , E. ; Lenhardt , L. ; Cigankova , V. ; Volacky , I. ; Maracek , I. (1999) . Microscopic analysis of the uterine endometrium in postparturient ewes . *Acta Vet. Brno.* 68 : 9 – 12 /
- 168- Grayling , J.P.C. ; Vanniekerk , C.H. (1991) . Involution of the post partum uterus of the boer goat . *J.S. afri. Vet. Assoc.* 62 : 4 – 9 .
- 19- Hoys, A.D. (1979) . The endometrial glands of the pregnant goat : an ultrastructural study . *J. Anat.* 112 : 40 – 57.
- 20- Aitken, R.J.; Burton, J. ; Hawkins, J ; Kerr – Wilson, R. ; Short, R.V. ; Steven. D.H. (1973) . Histological and ultrastructural changes in the blastocytes and reproductive tract of the roe deer , *Capreolus Capreolus* , during delayed implantation . *J. Reprod. Fert.* 34: 481 – 493.
- 22- Yamanchi , S. ; Kakishita , T. ; Kotera , M.K. (1969). Histological study of the pregnant uterus in the cow . 11 . *General histological study on the uterine glands* . *Bull. Univ. Osaka prefect ser.* 8 . 21 : 147 – 166 .