

EFFECT OF LOW LEVEL LEASER THERAPY ON THE CHRONIC DEFECT OF TIBIAL BONES IN RABBITS

Humam H.Nazht ,Sinan A.N. Al-khazrajii, Raffal A.Omar

Department of Surgery and obstetric ,College of veterinary medicine, University of
Baghdad,Baghdad ,Iraq.

Keys words: LLLT , Chronic bone defect,Tibial bone..

Corresponding Author;Humam_Nazhat@yahoo.com

ABSTRACT

This project was designed to evaluate the effect of low level leaser therapy (LLLT) on the induced chronic defect in the tibial bone of rabbits radiographically , and physically,eight adults local breed rabbits of both sexes were employed to induced 2.5 mm in diameter circular defect in the tibial bone surgically under general anesthesia and highly aseptic technique ,the induced hole was implanted with 2.5 mm stainless steel screw ,that removed from the bone after one and half month post operation , the experimental animals randomly divided into two equal groups four animas of each, the control group was lifted for normal healing process of the bone defect without any treatment ,while the treatment group was exposed daily with single dosage of continuous diode laser for five minutes of 850 nm and 148.4 j/cm² at 72 hours interval for 14 days post operation (p.o.) ,the radiographic results in the treatment group showed increase in the bone density around the induced defect with new bone formation fill the cavity at the end of 2nd week p.o. then increase in the bone density and volume at the end of 4th week p.o. compare with the control group that the density and the new bone formation less than treatment group ,the physical analysis revealed increase in the bone density and hardness with significant increase in fractures tolerance in the treatment group compare with the control group .In conclusion that the LLLT successfully used for repairing the critical (chronic) defect in tibial bones in rabbits .

INTRODUCTION

Chronic bone defect can be induced by removing the stainless steel screw implantation one month or more p.o. especially in the dentist researches, or after removing the internal and external fixation methods of bones fractures, these circular bone defect may be more or less than 2.5 mm (authors opinion), one of the best treatment methods of these defect are by bone grafts/implantation (1- 4) ,or even by laser therapy (5). laser can be used successfully for the repair of bone defect (6 the author himself) in which I refer in my work that laser therapy has appositve effect on the treatment of the bone defect of the lower mandible of rabbits ,that laser stimulated osteoblast cells. laser can be used strongly and successfully to promote fracture

healing (7-9), in which the mechanisms of laser can be done by increase bone metabolism, stimulation of collagen synthesis, angiogenesis, and it increase cells proliferation and differentiation of the mesenchymal cells, the increase osteoblast stimulation leads to osteon production and deposition with increase calcium and minerals deposition (10 and 11).

Low-power lasers therapy which (then called laser biostimulation) appeared before 1970s when Ender Mester trying to study the carcinogenic effect of laser on mice (12 and 13). Several in vitro and in vivo studies was done to evaluate the effect of laser on different cells (13). The aims of Laser therapy were to restore the normal biological function of injured or stressed cells (14). Many workers refer that laser can be used in acceleration of wound healing, acceleration remodeling and bone repair, restoration of normal neural function following injury, normalization of abnormal hormonal function, pain attenuation, stimulation of endorphin release, and modulation of the immune system (15). The indications of laser therapy are presented on both soft and hard tissues (16). Laser can be used for medical and Non-medical purposes, the most important applications are in the areas of major medical surgery, cosmetic and plastic surgery, dentistry and ophthalmology (17).

The mechanism of mode of action of laser as reported by (14) the laser photonic energy is absorbed by the mitochondria in the cell in which is converted to chemical kinetic energy and finally leads to more production of ATP. ATP is the source of energy in the cell which is necessary for cell activities such as synthesis of DNA, RNA and proteins that are important in cellular proliferation.

MATERIALS AND METHODS

Eight adults' local breed rabbits of both sexes were employed for induced hole of 2.5 mm diameter in the medial aspect of tibial bone, using the electrical drill under general anesthesia by intramuscular injection 17 mg /Kg .B.W. 2% xylazine hydrochloride after 10 minutes 37mg /Kg .B.W. 10% ketamine hydrochloride respectively, and to avoid thermal reactions by cooling the bone with dripping locally sterile cold normal saline during the operation, the induced pore were implanted with suitable size of stainless steel screw for 1 month and half p.o. (Fig.1 A), then the screw removed surgically and the animals divided to two equal group each has 4 rabbits (Fig.1 B), the control group lifted without any treatment, while the treatment group exposed to single daily dose of continuous diode laser at the medial side with a dose of (850 nm /148.4 J/cm for 5 minutes at 72 hours interval for 14 days). Daily observation for both group for 1 month after removing the stainless devices (two months and half p.o.). All the animals were radiographically examined at 15th and 30th days after removing the stainless steel screw, they scarified by high dose of anesthesia, the bone specimen sent for the physical lab analysis to estimate the bone density, bone hardness, and fractures tolerance (physical laboratory of the al-nahreen university).

RESULTS AND DISCUSSION

The radiographic finding of the treatment group 15th days after laser therapy revealed increase in bone density around the induced chronic defect (Fig.2 A), compare with the control group which lifted without laser irradiation, the area around the induced defect shown less density (Fig.2 B), and at the end of the one month's post irradiation the treatment group shown that the cavity filled with the new bone formation with the increase of the bone density around the induced hole(Fig.3 A), while in the control group the new bone formation and the bony density less than treatment group (Fig.3 B), and this is due to osteoblast stimulation by laser therapy which lead to osteon production and deposition, as well as increase mineral and calcium deposition (6,10, and 11). and this knots is consider with (18), that the a sclerotic area which appears high radiographic density is due to osteoblast stimulation and osteod formation and increase mineralization.

the high radiographic density around the induced critical defect with the new bone formation in the treatment group which appears more clear than the control group is due to effect of Laser therapy, which can used in accelerate fracture healing by increase in callus volume and mineralization due to osteoblast activity especially in early stages of healing process (10,19, and 20).

All the physical analysis shows increase in the bone density (Fig. 4) and hardness (Fig. 5) of the exposed group with LLLT, compare to the control group and this due to positive effect of laser therapy on osteoblast cells stimulation with osteon production and deposition and all these mentioned by (6,10, and 11). The increase resistance of bone fracture, in the treatment group compare with the control group which lifted without irradiation (Fig.6). Was because of the laser therapy, which result in increase hardness due to calcium and minerals deposition (10 and 11), and these statement agree with others authors which they mentioned that exposed to laser therapy can increase the amount of new bone formation and increase mineralized at the new bone tissue because of the laser stimulation on the osteblast cells (20), and these finding also agree with (18), that the hardness of the bone is due to the osteoblast stimulation and calcium deposition.

Laser accelerate, bone fracture healing by accelerating callus tissues formation and bone mineralize, due to osteoblastic activity, it enhance callus development in the early stage of the healing process, with improvement in biomechanical properties of the healing bone (10, 19, and 20). Many researchers declare that low intensity Laser irradiation in the early stage stimulating mineralization of new trabecular bone formation in surgically created bony defects (21 and 22).

CONCLUSION

LLLT can be used for the treatment of tibial critical (chronic) defect or cavities.

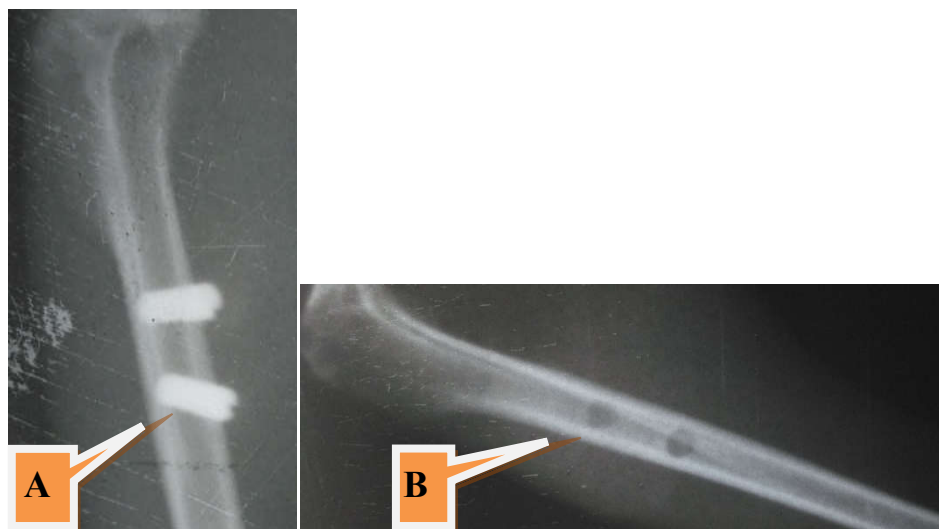


Fig. 1 A. implantation of the stainless steel screw remain for one and half month p.o.
B. Remove the stainless steel screw after one and half month's p.o.




Fig. 2 after 15th days post laser irradiation. Shown increase of bone density with new bone formation inside the bone defect more obvious in the treatment group A. than the control group B.

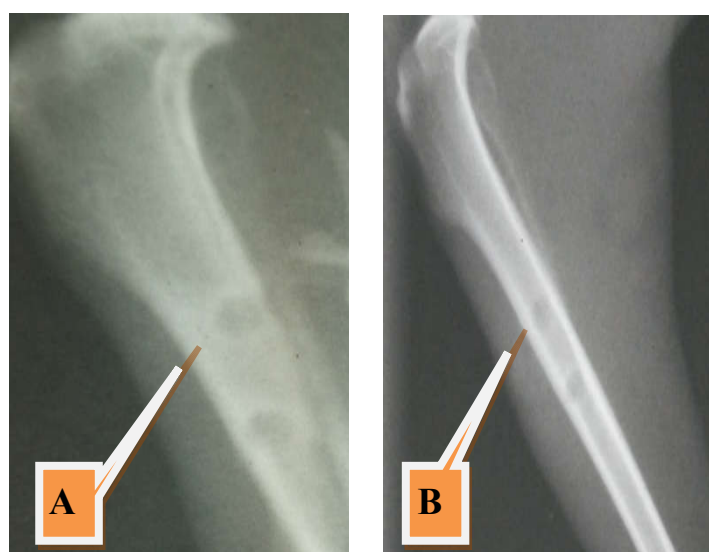


Fig.3 after one month after irradiation. A sclerotic area around the induced hole showed high radiographic density and fill the empty defect with new bone formation in the treatment group A. compare with the control group B.

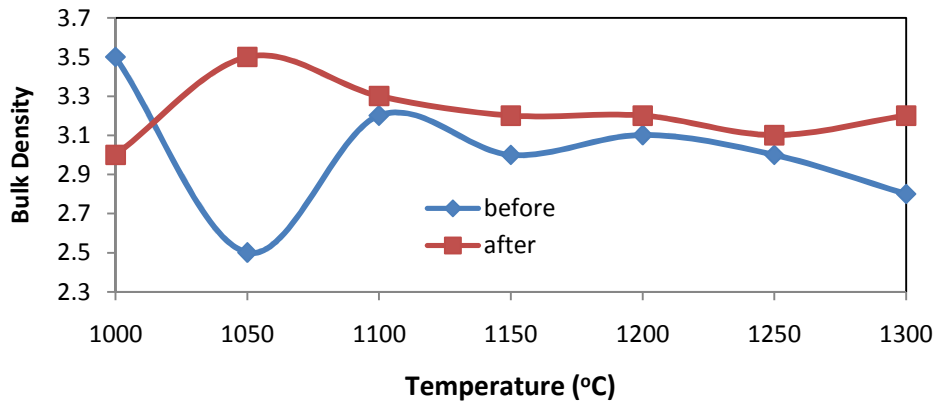


Fig. 4 increase bone density of the treatment group compare with the control group less and unstable.

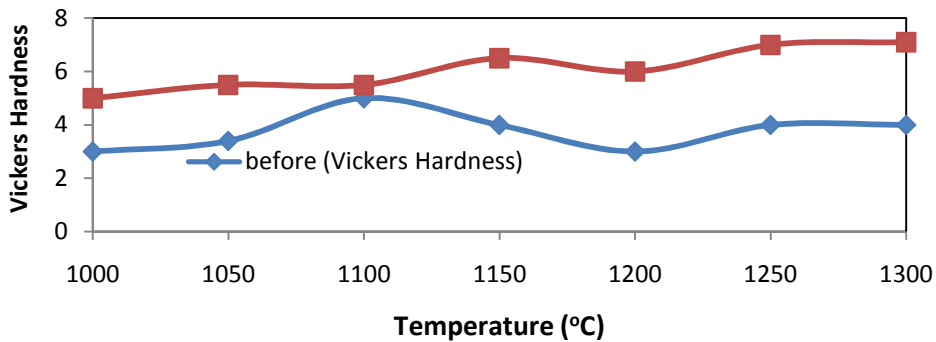


Fig.5 increase of bone density of the treatment group compare with the control group which show less and unstable

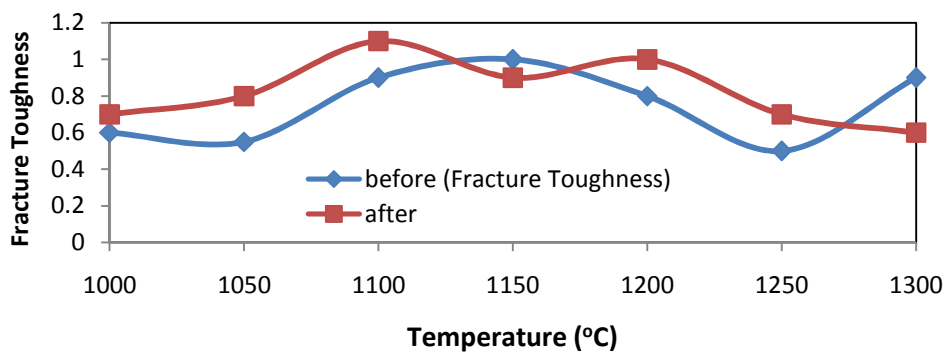


Fig .6 fracture tolerance in the treatment group more the control group

تأثير الليزر الواطئ الطاقة على الاصابة المزمنة في عظام القصبه في الارانب

همام حسام الدين محمد نزهت، سنان عدنان محمد نوري الخزرجي، رفل عبد الدايم عمر

فرع الجراحة والتوليد البيطري، كلية الطب البيطري، جامعة بغداد، العراق

الخلاصة

صمم هذا البحث لدراسة تأثير استخدام الليزر واطئ الطاقة على الاذى المحدث في عظم القصبه في الارانب. استخدمت ثمانية ارانب ناضجة محلية من كلا الجنسين لاحداث ثقب دائري بقطر ٢.٥ ملم في عظم القصبه جراحيا تحت التخدير العام وباستخدام شروط التطهير والتعقيم المتعارف عليها، وذلك بزرع قطعة من (stainless steel) بقطر ٢.٥ ملم ثم تم رفعها بعد شهر ونصف من العملية. تم تقسيم حيوانات التجربة الى مجموعتين متساوية كل مجموعة تحوي اربع ارانب. مجموعة السيطرة تركت للمراقبة بدون اية تعريض، اما مجموعة العلاج فقد تم تعريض منطقة العملية الى جرعة واحدة يوميا من الليزر واطئ الطاقة نوع الليزر المستمر لمدة خمسة دقائق بطاقة ١٤٨.٤ جول /سم^٢ بطول موجي ٨٥٠ نانو ميتر كل ٧٢ ساعة لمدة ١٤ يوم من التعريض. واستمرت المتابعة لمدة شهرين ونصف من العملية واستخدمت الفحوصات التالية: الفحوصات الاشعاعية للفترات اسبوعين واربع اسابيع بعد التعريض. والفحوصات الفيزيائية لقياس مستوى الكثافة والصلادة وقابلية تحمل الكسر لمنطقة التعريض بالليزر. وظهرت نتائج الفحوصات الاشعاعية بظهور كثافة عظمية في منطقة التعريض حول الثقب للفترة اسبوعين بعد التعريض واستمرت كثافة العظم المتكون حول وداخل الثقب مقارنة مع مجموعة السيطرة الذي لم يكن بالكثافة والوضوح في مجموعة العلاج.

اما نتائج الفحوصات الفيزيائية فقد بينت وجود زيادة في كثافة العظم والصلادة مع زيادة واضحة في قابلية التحمل للكسر في منطقة التعريض في مجموعة العلاج مقارنة مع مجموعة السيطرة.

نستنتج من هذه الدراسة هو ان الليزر واطئ الطاقة ممكن استخدامة في علاج الاصابات المزمنة المستحدثة في عظام القصبه في الارانب

REFERENCES

1. Matsumine, A.; Myoui, A.; Kusuzaki, K.; Araki, N.; Seto, M. and Yoshikawa, H. et al., (2004). Calcium hydroxyapatite ceramic implants in 5. bone tumour surgery. A long-term follow-up study. J Bone Joint Surg Br; 86:719–25.
2. Ogose, A.; Hotta, T.; Kawashima, H.; Kondo, N. and Gu W, Kamura T, et al. (2005). Comparison of hydroxyapatite and beta tricalcium phosphate as bone substitutes after excision of bone tumors. J Biomed Mater Res B Appl Biomater; 72:94–101.

3. Walsh, WR.; Vizesi, F.; Michael, D.; Auld, J.; Langdown, A. and Oliver, R. et al. (2008) .Beta-TCP bone graft substitutes in a bilateral rabbit tibial defect model. *Biomaterials*; 29:266–71.
4. Nazht, H.H.; Omar, R.A. and Ahmed, H.K.(2018a): Sheep rib xenograft femoral bone implant in rabbits *OJVR* .Volum22 (4) : 290,299.
5. Hallman, M. and Thor, A. (2008). “Bone substitutes and growth factors as an alternative/complement to autogenously bone for grafting in implant dentistry,” *Periodontology*. 47, (1): 172–192.
6. Nazht, H.H.(2013).Histopathological study of the effect of the laser on the osteoblast cells during mandible defect in rabbits, *AL-Anbar J.Vet. Sci.*,Vol.6 No. (2).
7. Nazht, H. H. ; Faleh I. B.and Hamed N.A. (2016). Histopathological Study of the Distal Third Fractures of Radius in Dogs, Treated with LLLL, *Bas.J.Vet.Res.*Vol.15, No.1.
8. Nazht ,H. H. and Hamed,N. A. (2017) .Radiological Effect of the Low Level Laser Therapy on Fracture Healing in the Distal Third of Dogs. *Elixir Hor. & Sig.* 107 42209-42211
9. Nazht, H.H.; Omar, R.A.; AlDahan, R.A;and Ahmed H.K.(2018b). Effect of Low Level Laser Therapy on the Sheep Ribs Xeno Graft in the Treatment of Rabbits Long Bone Fractures. *Global Proceedings Repository, American Research Foundation*. Available online at <http://proceedings.sriweb.org> . The Ninth International Scientific Academic Conference. Under the Title “Contemporary trends in social, human, and natural sciences”
10. Shakouri, S K.;Soleimanpour, J.;Salekzamani, Y.and Oskuie,M. R.(2010). Effect of low-level laser therapy on the fracture healing process. *Lasers*, Volume 25, Issue 1, pp 73-77.
11. Merli, L.A.; V. P. de Medeiros, V.P. and Toma, L. (2012). “The low level laser therapy effect on the remodeling of bone extracellular matrix,”*Photochemistry and Photobiology*.88, (5):1293–1301.
12. Michael, R.; Hamblin, Tatiana N.;and Demidova. (2006) Mechanisms of low level light therapy. *proc. Of SPIE*; 6140,614001.

13. Blaya, D. S.;Pozza,D.H.;João Batista Blessmann Weber,J.B.B.; de Oliveria,M.G. (2008) Histological study of the effect of laser therapy on bone repair. The journal of contemporary dental practice, 9 (6)
14. Hawkins. and Abrahamse.(2007).Phototherapy-a treatment modality for wound healing and pain relief. African Journal of Biomedical Research. 10:99-109
15. Walsh L.J. (1997) A current status of low level laser therapy in dentistry. Part I soft tissue applications. Australian Dental Journal; 42:4
16. Carmen D. M. Todea. (2004).Laser application in conservative dentistry. TMJ; 54:(4)
17. Jan Bone. (2008).Opportunities in laser technology careers, ch.3 pp. 34-46 Mc Graw Hill.
18. Marsell, R.and Einhorn, TA. (2011).The biology of fracture healing, Injury; 42:551–555.
19. Prado-Filho, J.C. and Sterman, F.A. (2004). “Evaluation of mineral bone density in thoroughbred horses under an initial trainingprogramme,” Brazilian Journal of Veterinary Research Animal Science, 41(6): 384-388.
20. Lirani-Galvão, AP.; Jorgetti, V.' da Silva, OL. (2006).Comparative study of how low-level laser therapy and low-intensity pulsed ultrasound affect bone repair in rats. Photomed Laser Surg.;24(6):735-40.
21. Dortbudak, O.; Haas, R.; and Mallath-Pokorny G.(2000).Biostimulation of bone marrow cells with a diode soft laser. Clin Oral Implants Res.Dec;11(6):540-545.
22. Cerqueira, A. ; Silveira, RL. ; Oliveira, MG. de. ;and Sant’anaFilho M and Heitz C: (2007). Bone tissue microscopic findings related to the use of diode laser (830 nm) in ovine mandible submitted to distraction osteogenesis. Acta Cir Bras 22: 92-97..