

WANDERING THYROID FOLLICLES WITHIN THE RENAL TISSUE OF CARP FISH "*Cyprinus Carpio*".

Amer M. Hussin

College of Veterinary Medicine, University of Baghdad, Baghdad, Iraq.

(Received 14 September 2015 ,Accepted 12 november 2015)

Key words: Carp fish., Thyroid follicles., Winter.

ABSTRACT

Twenty healthy adult Carp fish were collected from Dijlah river in Iraq in Summer and winter times of the year (Ten for each). The fish were sacrificed and fixed in 10% neutral buffered formalin solution. Routine histological preparations were carried out. Hematoxylin - Eosin stain was used. The finding of the current study showed that clear connective tissue capsule was not observed. Instead, wide loose connective tissue was surrounded the follicles. The thyroid follicles were distributed individually or in groups in the kidney and sub pharyngeal region(around the ventral aorta). The thyroid tissue was represented by thyroid follicles of different sizes and shapes. In Carp fish, the building up and organization of the follicular cells of thyroid follicles were simple and poorly organized. There was a close relationship between the morphological state of thyroid follicles and the season(temperature). The results of the present study also demonstrated that the spread of thyroid follicles in summer was more than in winter where the follicles appeared as aggregated at the periphery of renal tissue and also the results of this study showed that large and small follicles were combined. The study also registered that, during winter, the large follicles were mostly formed by the aggregation of smaller ones and that according to the physiological status of the thyroid tissue. The study concluded firstly that these follicles had the ability to wandered within the renal tissue. Moreover, the study concluded that the thyroid follicle was dynamic structure, and their sizes depending on the amount of colloid present within .



INTRODUCTION

Thyroid tissue in fish has been found in different organs including ovary ; Kidney, spleen, heart, eye, intestine (10,16). (2& 3) reported that thyroid gland of fish could be observed In the gut, gonad, liver, spleen, eye and Brain. It has variable shapes and sizes in different fish species; It may be variably represented by a group of follicles in cyclostomes, forming diffuse structure in the form of small masses in many teleosts; forming a compact structure in elasmobranches and bony fishes; and comprises a pair of interconnected lobes in dipnoi. The activity of thyroid tissue can be influenced by season and some physiological conditions (12 &14). It has been suggested that temperature may play a role in regulation of seasonal thyroid activity (5). (1) reported that the peak of activity of thyroid follicles in fish was increased significantly during midsummer(August).

MATERIALS AND METHODS

Twenty healthy adult female Carp fish were obtained from Dijlah river in Iraq in summer and winter times (Ten fish for each season) during the months July and December respectively in 2014. The fishes were sacrificed, the tissue samples were prepared and fixed in 10% neutral buffered formalin solution for 72 hours. Routine histological preparations were carried out. The tissue sample was dehydrated using an ethyl alcohol series and then embedded in paraffin. Samples were sectioned at (5-7)um and slides were stained with Hematoxylin & Eosin stain (17). Examination was carried out using light microscope (Olympus). The diameter and density of thyroid follicles, the number of follicular cell/follicles were measured. The height of the follicular cells was calculated in a total of 15 follicles per fish. Four points in each follicle at 90 degree from each another were selected (6).

RESULTS

The current investigation revealed that the thyroid follicles of Carp fish were disseminated throughout the renal tissue and subpharyngeal region (around the ventral aorta). The study demonstrated the presence of different sizes and shapes of thyroid follicles i.e., follicles present singly or in groups (Fig. 1& 2 and table 1). A well defined connective tissue capsule could not be demonstrated and the follicles were widely separated by the interstitial tissue and most of these thyroid follicles were nearly filled with colloid substance. The results of this study also reported that during



summer time, the thyroid follicles of Carp fish were homogenously distributed all over the renal tissue (Fig.1), and aggregated at the periphery of that tissue in winter (Fig.2) . The present study was considered as a first record that some thyroid follicles were closely combined with each other (Fig. 3 & 4) forming large thyroid follicle. Table 1 showed that the density of follicles and height of follicular cells were at higher values in summer, while the diameter of follicles and the number of cells/follicle were also at higher values in winter.

Table.1. showing diameters , densities , heights and number of cells/follicles in summer and winter.

Diameter of follicles (um)						
Season	Head of kidney		Kidney		Sub pharyngeal region	
	Small	Large	Small	Large	Small	Large
Summer	28±1.15*	70±4.5*	41±2.9*	87 ± 4.1*	48 ± 2.9*	99.8± 1.3*
Winter	44±2.2	86±3.6	50±1.1	99.6± 3.1	65.2± 4.5	166.2± 2.5
Season	Density of follicles / mm ²					
Summer	14 ± 0.88*		5.2 ± 1.4*		3.9 ± 0.2*	
Winter	8.2 ± 2.8		4.4 ± 0.9		2.8 ± 0.33	
Season	Height of follicular cells (µm)					
Summer	5.5 ± 0.18*		5.3 ± 0.18*		3.9 ± 0.18*	
Winter	2.9 ± 0.4		2.9 ± 0.18		2.7 ± 0.30	
Season	Number of cells / follicle					
Summer	17.1 ± 1.22*		22.2 ± 2.0*		20 ± 2.2*	
Winter	19.90 ± 2.9		26.5 ± 1.98		23 ± 2.9	

*There was a significant differences at the level of (P>0.05). values expressed as mean ± SE.



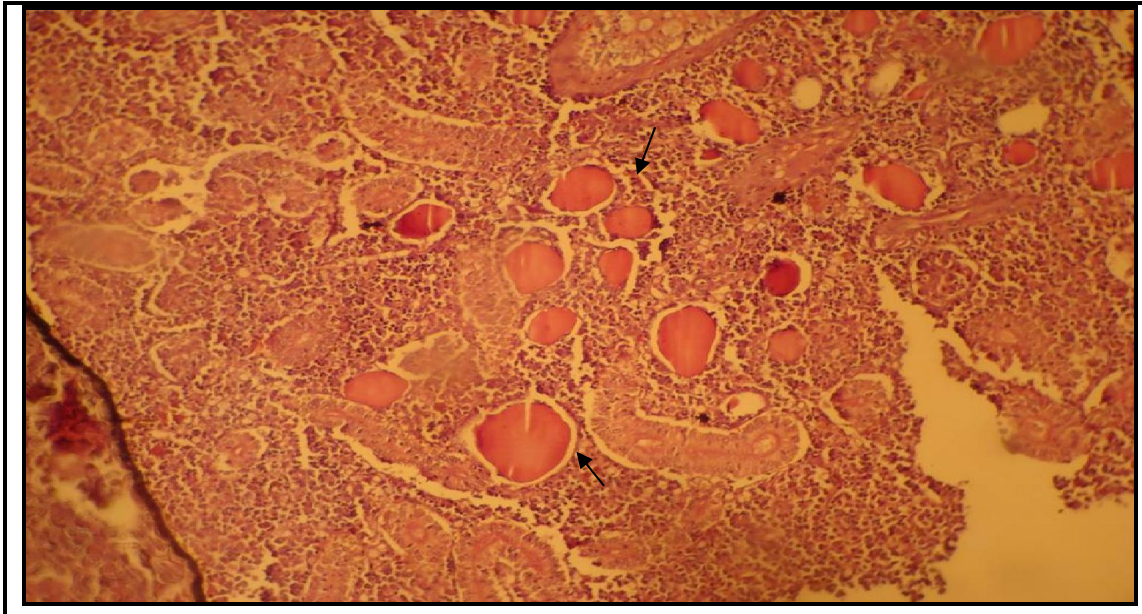


Fig. 1. A photomicrograph showing the thyroid follicles (arrows) within the renal tissue of Carp fish in summer . Note the disseminating pattern and the homogenous distribution of these follicles . H& Eosin stain. X 200.

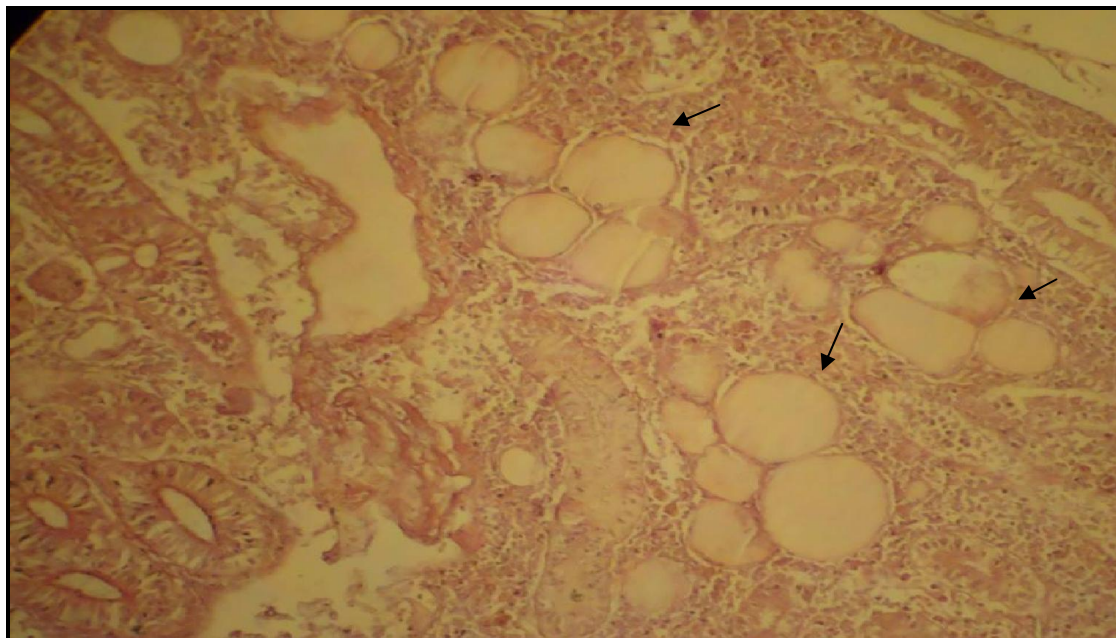


Fig. 2. A photomicrograph showing the aggregation of thyroid follicles (arrows) within the renal tissue of Carp fish in winter. H&E stain. X 200.



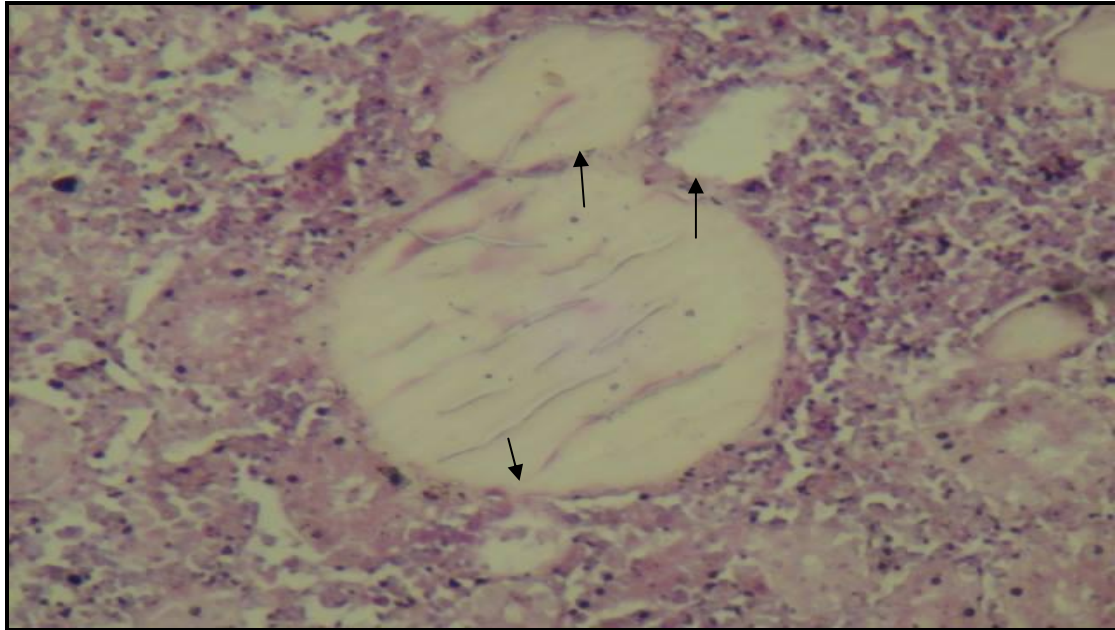

Fig. 3. A photomicrograph showing the thyroid follicles of Carp fish in winter. Note the attachment between the large and small ones (arrows).H&Estain.200X 200.

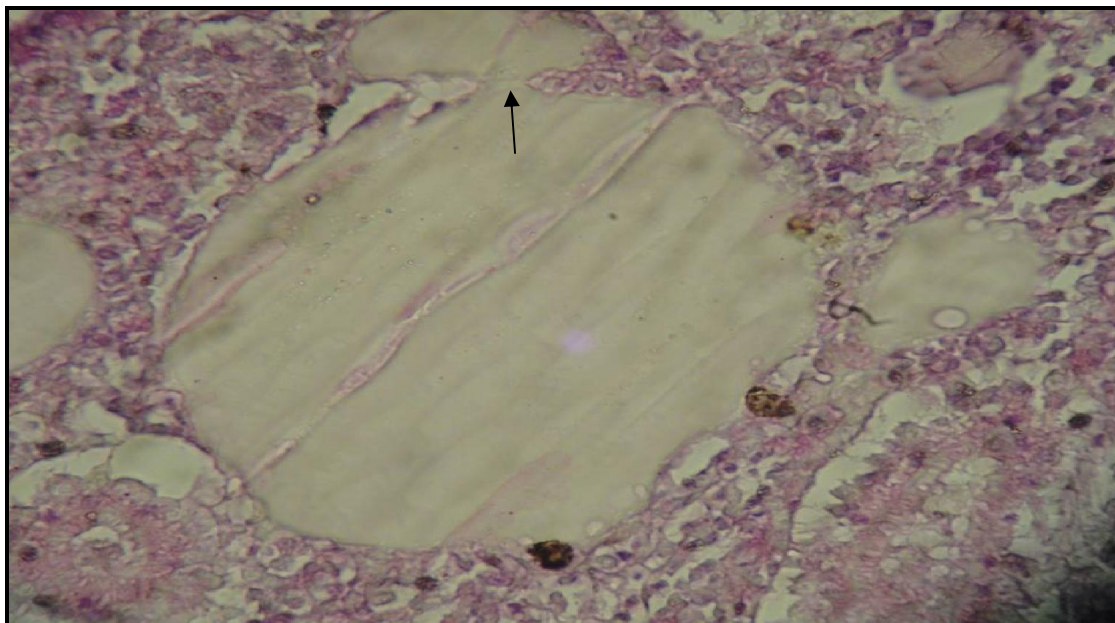


Fig. 4. A photomicrograph showing the high magnification of Thyroid follicles in winter. Note the point of attachment between large and small ones (arrow). H&E stain. X 400.



DISCUSSION

The current study reported that, the thyroid tissue of *Cyprinus Carpio* fish unlike other teleost fish is not in the form of compact gland and is found in the head of kidney, kidney and subpharyngeal region (around ventral aorta). However, other researchers reported that the thyroid follicles of Teleost fish were not localized in one region as in other vertebrates, but disseminated and distributed all over the body like, kidney, Spleen, Liver, Gut, and heart (16), in sub pharyngeal region (around the ventral aorta) (1) , eye (15) , gonad (18), and brain (4). The lack of well defined capsule may explains and confirms the migration of thyroid follicles in different regions of the body. This was in agreement with (1). In winter, the activity of thyroid gland was suggested to be hypoactive as the follicles were aggregated at the periphery of the renal tissue and appear mostly filled with thick coagulated colloid whose follicular cells were mostly squamous. On the other hand, the activity of thyroid gland in summer was noticeably active , as the follicles were homogenously distributed and nearly filled with diluted homogenous colloid and lined mostly by cuboidal cells. No markedly hyperactive follicles exhibiting columnar follicular epithelial cells were observed. This was confirmed by (5, 8, 1), and (7) who reported an increase in the thyroid follicular activity and production of triiodothyronine (T3) and thyroxine (T4) in summer . The above observations indicated that the thyroid follicles of fish have the capability of adaptation by moving and wandering in the renal tissue . The dissemination phenomena of thyroid follicles may compensate and cover the simplicity of the unidirectional blood circulation of fish, This was because the thyroid tissue, as any other endocrine tissue , requires rich blood supply to cover the exceeded seasonal need of the body. On the other hand, Large thyroid follicle comes from the combination of smaller ones. The location of thyroid gland varies considerably in different fish species(2) , All the above mentioned statements confirms that the thyroid follicles were a dynamic structures and wandered according to the functional need. This may explains the less organization and obviousness of the follicular cells in thyroid follicles of fish compared to the well- organized follicular cells of thyroid follicles in vertebrates (13). The presence of the thyroid



tissue in many regions of the body of the fish, the seasonal difference in the distribution of the follicles, The lacking of the capsule, and the irregularity of the shape of the thyroid follicles, all these indicate that the thyroid follicles were dynamic structures had the capability to move and migrate within the renal tissue.

CONCLUSIONS

The present work concluded that there was a proportional relationship between the environmental temperature and the thyroid activity and there was also a reverse relationship between the activity and the quantity of colloid in thyroid follicles. In addition, the thyroid follicles were not fixed but seasonally wandered within the renal tissue. It was also concluded that the different thyroid follicles were attached to each other and that large follicle arises from the combination of many smaller ones. The study revealed also that the shape and size of thyroid follicle was not static and depends on the amount of the colloid present within the follicle.

وجود جريبات درقية متحركة بداخل النسيج الكلوي في أسماك الشبوط (المبروك) *cyprinus carpio*

عامر متعب حسين

فرع التشريح، كلية الطب البيطري، جامعة بغداد، العراق

الخلاصة

إجريت الدراسة الحالية لمعرفة تأثير تغيرات البيئة على نسيج الدرقية في أسماك الشبوط. لهذا الغرض جمعت عشرون من أسماك الشبوط البالغة (عشرة في كل فصل) في شهري الصيف والشتاء من نهر دجلة في العراق. تم تحضير العينات ثم ثبتت بمحلول 10% الفورمالين الداريء المتعادل . أجريت التحضيرات النسجية الروتينية ثم صبغت العينات بصبغة الهيماتوكسلين والأيوسين. لم تلاحظ الدراسة وجود محفظة واضحة تحيط بالجريبات ، وبدلا عن ذلك، أحيطت الجريبات الدرقية في أسماك الشبوط بنسيج رابط رخو. ظهر النسيج البيني بين الجريبات وفيرا. إنتشرت الجريبات بشكل منفرد أو بشكل مجاميع بداخل نسيج الكلية أو المنطقة تحت البلعومية (حول الأبر البطنية). ظهر النسيج الدرقي على هيئة جريبات مختلفة الأحجام والأشكال. يكون بناء وتنظيم الخلايا الجريبية في أسماك الشبوط بسيط وغير منتظم. بينت الدراسة وجود علاقة وثيقة بين الحالة



الشكلية للجريبات والموسم (درجة الحرارة) حيث كان إنتشار الجريبات صيفا أكثر منه شتاء حيث ظهرت الجريبات شتاء متجمعة في محيط النسيج الكلوي..إضافة الى ذلك أظهرت الدراسة وجود إتصال بين الجريبات الكبيرة والصغيرة خاصة عند فصل الشتاء حيث بينت الدراسة أن الجريبات الكبيرة تنشأ أصلا من إتحاد الجريبات الصغيرة . إستنتجت الدراسة لأول مرة أن للجريبات الدرقية القابلية على الحركة داخل النسيج الكلوي ،إضافة الى ذلك إستنتجت الدراسة أن الجريبات هي تراكيب ديناميكية غير ثابتة الحجم وإن حجمها يعتمد على كمية الغروان الموجود بداخلها.

REFERENCES

1. Abbas, H. H. , Authman, M. M. , Zaki, M. S., and Mohamed G F. (2012). Effect of seasonal temperature changes on thyroid structure and hormones secretion of white Grouper (*Epinephelus Aeneus*) in Suez Gulf, Egypt.
2. Abu Naser, S.M.(2012). Internet, en. Bdfish.org/2012/04/introduction-of-endocrine-glands-of-fishes.
3. Aughey, E. and Fry, F.L. (2010). Comparative veterinary histology. 2nd ed. Manson publishing. England.p:154.
4. Baker, K. F. (1958). Heterotropic thyroid tissue in fishes. I. The origin and development of Heterotropic thyroid tissue in platyfish. J. Morphol. 103, 91-129.
5. Comeau, L. A. ; Campana; S.E; Hanson, J.M. and Chouinard, G.A (2000). Seasonal changes of thyroid hormones in field-collected Atlantic cod in relation to condition indices, water temperature and photoperiod. Journal Of Fish Biology, 57: 571-588.
6. Halasz, P. and Martin, p. (1985) : Megellan: Program for quantitative analysis of histological sections. School of anatomy, University of New South Wales, Australia.
7. Loter, T. C.; MacKenzie, D. S.; McLeese, J. and Eales, J. G. (2007) .Seasonal changes in channel catfish thyroid hormones reflect increased magnitude of daily thyroid hormone cycles. Aquaculture, 262:451-460.
8. Ortiz- Delgado, J. B.; Ruane, N. M.; Pousao- Frreira; Dinis, M. T. and Sarasquete, C. (2006). Thyroid gland development in Senegalese sole (*Solea senegalensis* Kaup 1858) during early life stages: A histochemical and immunohistochemical approach. Aquaculture, 260: 346-356.



9. Pandey, K. F, Shukla, J. P. (2007).; Fish and Fisheries (2nd ed), Rakesh Kumar Rastogi Publications, Gangotri Shivagi Road, Meerut, India. PP.20.
10. Power, D. M, Liwellyn, L, Faustino, M, Nowell, M. A ,Bjonnsen, B. T, Einarsdottir, I. E, Canario, A. V, Sweeney, G. E. (2001).Thyroid hormones in growth and development of fish. *Comp Biochem Physiol c Toxicol Pharmacol* 130(4):447-59.
11. Robert, B. and Moeller, J (2015). Biology of Fish. WWW.CiChlid-forum.Com/articles/biology-of-Fish.Php.
12. Rolland, R. (2000). A review of chemically-induced alterations in thyroid and vitamin A status from field studies of wildlife and fish. *J. Wildl. Dis.*, 36: 615-635.
13. Samuelson, D. A. (2007). Text book of Veterinary Histology. Saunders, Elsevier. China. P:407.
14. Schnitzler, J. G. ; Klaren PHM.; Bouquegneau, JM and Das K (2012). Environmental factors affecting thyroid function of wild sea bass(*Dicentrarchus Labrax*) from European coasts. *Chemosphere*, 87: 1009-1017.
15. Schubert, G. (1969). Exophthalmus caused by thyroid tissue in the choroid layer of the eye in *Coris gaimard*. *Bull. Wildlife disease Assoc.* Vol. 5. P:113.
16. Sugiyama, S. and Sato, T .(1959).Histological studies of the renal thyroid of the bony fish in comparison with the pharyngeal thyroid. Presented at the 18th Kanto-regional and 19th Chubu-regional Meetings of the Japanese Association of Anatomists, at Shinshu university school of Medicine, Matsumoto.
17. Suvarna, S. K; Layton, C. and Bancroft, J. D. (2013). Bancroft's theory and practice of histological techniques. 7th ed. Churchill livingstone, Elsevier limited.
18. Weber, G. M.; Okimoto, D. K.; Richman, III and Grau, E. G. (1992). Patterns of thyroxin and triiodothyronine in serum and follicle-bound oocytes of the tilapia, *Oreochromis mossambicus*, during oogenesis. *General and Comparative Endocrinology*, 85: 392-404.

